

Bioderma Congress Reports

AAD 2023

Reports written by

Dr. Ben Esdaile

Consultant Dermatologist, UK

Therapeutics hotline

The first speaker was **Linda Stein Gold** from Detroit who talked about new therapeutics in Acne and Rosacea. In terms of new topicals for acne she discussed some exciting results with a formulation being able to combine tretinoin and benzoyl peroxide using microencapsulated tretinoin (normally BPO inactivates tretinoin). The studies appear to show that a once daily application is effective and well tolerated. A new androgen receptor antagonist – Clascoterone appears to have promising results including a reduction in sebum production. She also highlighted a study showing the potential benefits of triple combination therapy (clindamycin, benzoyl peroxide and adapalene) that appeared to show superiority to a double combination. She discussed a novel tetracycline (sarecyline) that appears to be effective as well as leading to reduced antibiotic resistance. In Rosacea, mast cells appear to play a role and there may be a place for possible topical and oral mast cell stabilisers in therapy. Topical minocycline foam studies show excellent responses at 12 weeks with minimal side effects as well as promising results with low dose minocycline. Finally, she presented some interesting results with 5% Benzyl peroxide in rosacea when encapsulated with almost 50% efficacy and surprising tolerability.

Darrell Rigel from New York talked about new therapeutics in skin cancer. In terms of actinic keratoses, he discussed the benefits of Tirbanibulin ointment with its lower side effect profile. He discussed a paper showing that pain related to conventional PDT can be reduced by immediately placing patients under the lamp instead of waiting. The pain reduces without a loss of effectivity. He mentioned L-carnitine to help reduce muscle cramps as a side effect of Hedgehodge pathway inhibitors in advanced Basal Cell Carcinoma. He also highlighted the effectivity of nicotanimide at a dose of 500mg twice daily to help reduce the occurrence of non-melanoma skin cancers in those at risk. He finished his talk with an update on the prediction of a positive Sentinel Lymph Node biopsy and highlighted the lack of benefit from completion of lymph node dissection in those with positive results. He highlighted some interesting studies on tumour-infiltration lymphocyte therapy in metastatic melanoma as well as several studies seeming to show that propranolol appears to improve survival in metastatic melanoma.

Jerry Shapiro from New York gave an update on some fascinating novel topical therapies for androgenic alopecia including clascoterone 2.5% -7.5% solution twice daily, topical finasteride spray 0.25% with the potential benefits of avoiding systemic sexual side effects and topical valproate 8.3%

spray. These can also be combined with topical minoxidil (3%). He also discussed mesotherapy with microinjections with dutasteride (every 3 months) and minoxidil (every 1-2 weeks) with limited side effects compared to the oral alternatives.

He discussed the adjuvant role of oral minoxidil in alopecia areata particularly alongside the JAK inhibitors. He also went on to discuss the potential use of 10% metformin cream in scarring alopecias (such as CCCA).

Pearl Grimes from Los Angeles gave updates on pigment therapies. She highlighted the multimodality approach to managing melasma with a number of agents. She discussed the vital importance of good photoprotection particularly against visible light with tinted iron oxide and/or titanium dioxide. She discussed the importance of antioxidants including niacinamide and grape seed extract as well as non-hydroquinone agents including cysteamine, thiamidol, tranexamic acid and malassezin. She also discussed the potential role of mast cell inhibitors and the fact that 50% may have vascular melasma and could benefit from vascular laser, tranexamic acid or H1 and H2 antihistamines. She went on to show some exciting new data on the role of topical JAKi in vitiligo with Ruxolitinib phase 3 studies. She showed this is also being used in combination with UVB phototherapy with efficacious results.

Mark Lebwohl from New York discussed new treatment options in psoriasis. He showed that one infusion of an IL-36 blocker - spesolimab can control severe generalised pustular psoriasis extremely rapidly. He showed the results of a study with Bimekizumab (IL-17 blocker) for chronic plaque psoriasis working extremely effectively with almost 60% of patients obtaining a PASI 100 in 16 weeks. He showed promising results with an oral JAKi (TYK-2 inhibitor) - Deucravacitinib as well as topical PDE4 inhibitors.

Antonella Tosti from Miami talked about what's new in nail therapies. Minoxidil can potentially increase nail growth by improving blood flow. She presented data from a study of low dose oral minoxidil used in hair loss where patients were questioned about their nails. She suggested a 1.25mg dose of oral minoxidil may be useful in patients with brittle or fungal nails. She also showed evidence that oral JAKs used to treat alopecia areata appears to also potentially lead to an improvement in nail psoriasis and nail lichen planus. She then brought to our attention the possible role of HPV vaccination in recalcitrant periungual warts and the potential benefit of botulinum toxin injections in the hands for yellow nail syndrome. She recommended the use of topical 0.5% timolol for periungual pyogenic granulomas and finally highlighted that fact that patients taking Biotin supplements for their hair and nails should be advised to stop this one week before any blood tests as this can interfere with some of their blood results.

Lawrence Eichenfield from San Diego gave an update of new therapeutics in paediatric dermatology. He highlighted trial data of the efficacy with non-steroidal topicals in atopic dermatitis with topical Ruxolitinib 1% cream (JAKi) as well as Roflumilast cream 0.15% (PDE-4 inhibitor), Topinarof 1% cream (AhR agonist) and Crisaborole 2% ointment (PDE-4 inhibitor). In terms of systemic medications, Dupilumab is now approved to down to 6 months of age in atopic dermatitis whereas other systemics including Upadacitinib, Abrocitinib and Tralokinumab are available for adolescents.

Henry Lim from Detroit concluded the session with an update on photoprotection. He started by highlighting the ongoing debate about the potential environmental effects of organic UV filters on the coral reefs. The report of the National Academies highlighted that more studies need to be done but there are potential risks to humans not properly protecting their skin as well as some evidence that low doses of the UV filters can be damaging to the coral reef. The concentrations in the trials may be higher, however, than those actually found in nature.

He discussed new developments in sun protection with some new organic filters against long UVA – Mexoryl 400 (long UVA) and TriAsorB (long UVA). He highlighted that fact that many current organic filters have limited protection against visible light and longwave UVA and we are still reliant on tinted sunscreens containing iron oxide and titanium oxide. He talked about the potential role of antioxidants in sunscreens to protect against the damage caused by free radicals and finally he talked about the future of more personalised photoprotection with different needs of different skin types in regards to UVA, UVB and high energy visible light protection.

Augmented Intelligence and its role in enhancing the practice of dermatology

The moderated panel discussion consisted of US dermatologists Carrie Kovarik, Veronica Rotemberg, Roberto Novoa and Mustafa Jafry, who discussed the current state of Artificial Intelligence (AI) and Augmented Intelligence (Aul) in dermatology in the US. The panelists started by noting that there are currently no FDA-approved image-based AI models/systems in dermatology in the US.

The panel then discussed how to try and explain AI and Aul to family, friends, colleagues, and patients, noting that AI can potentially improve performance by using computers to process data.

They explained that an AI system needs to be trained on specific data and can make mistakes if it is shown data that it has not been trained on.

The panel also discussed the potential impact of AI on the medical profession and whether AI will eventually replace dermatologists. They noted that while AI can do a lot of the work, human decision-making is still required, and there are many medical-legal aspects to consider. The example of the air industry was discussed that a plane still needs 2 pilots despite 95% of the work being done by autopilot.

The panel also discussed the importance of data in AI and the biases that can exist in data. They noted that data has been called the 'new oil' and that there are many biases in data, such as those caused by marker pens, stickers, and rulers on images.

Finally, the panel discussed exciting developments in the AI landscape, such as the FDA's increased focus on dermatology devices and the potential for evidenced-based AI solutions. They also touched on the importance of consent when it comes to data, including data consented for AI, and the potential sale of patient data.

The panel also discussed the power of generational AI and the use of software such as Chat GPT4 to write content.....**

This summary was created by putting my notes into Chat GPT4

Advanced dermoscopy

The session was started by the current International Dermoscopy Society President **Aimilios Lallas** from Greece. He discussed the dermoscopy of nail pigmentation in regards to pigmented nail bands and gave us 7 tips for assessing melanonychia striata to try and pick up melanoma. Step 1 is to first exclude haemorrhage (beware rarely melanoma can present under a haemorrhage). Step 2 is to consider the patient's age as in children melanonychia is almost always a naevus despite the bands often looking ugly. Acral melanoma below the age of 30 is extremely rare. Step 3 is to check if other nails are involved as if multiple unlikely to be melanoma. Step 4 is to check the free edge of the nails for conditions such as onychopapilloma. Step 5 is to assess whether there is a melanocytic proliferation or melanocytic activation with brown being more likely in melanocytic proliferations and grey in melanocytic activation. Step 6 is to assess the size of the band with concern if the band covers

more than 50% of the nail. Step 7 is to assess whether the band is regular or irregular with irregular bands being seen in melanoma. He finally suggested looking back at the origin of the nail band at the matrix as this gives a retrospective view of many months as to the nature of the proliferation.

Wilhelm Stoltz from Germany reviewed pigmented lesion on the face. He highlighted the special criteria due to different facial anatomy with no rete ridges compared to the body. He warned you don't get new benign melanocytic lesions in sun-damaged adult skin on the face so beware of reports of benign melanocytic proliferations. He went on to discuss tips on the early recognition of lentigo maligna with the importance of recognising benign patterns is the main differentials including solar lentines, seborrhoeic keratoses and pigmented actinic keratoses. He described benign patterns as mainly brown with grey or blue-grey being a bad sign. He suggested looking for milia-like cysts on non-polarising dermoscopy as a helpful clue to seborrhoeic keratoses. He went on to discuss his algorithm and a newer inverse approach to help detect early lentigo maligna with the earliest clues being asymmetrical follicular pigmentation before slate grey dots and globules and a rhomboidal pattern.

Next **Susana Puig** from Spain gave a review of the differential diagnoses of scalp lesions. She highlighted the dangers of hidden sites by hair. She discussed features of common benign naevi in the scalp including naevi with central hypopigmentation. She discussed the dangers of some blue scalp naevi and showed some features of early melanoma can be subtle especially in sun-damaged skin. She then showed a number of peculiar dermatoscopic patterns of scalp melanoma and the take home message was that If you don't recognise any pattern then melanoma is in the differential. Although only 5% of all melanomas are in scalp they have a high mortality rate due to late diagnosis.

Nisa Akay from Turkey discussed acral melanocytic skin lesions. She showed common benign patterns to recognise including the parallel furrow pattern, the fibrillar pattern and the lattice pattern. She also highlighted some variations of the parallel pattern including the double dotted pattern. She then showed a number of cases using the BRAAF algorithm to try and detect acral melanoma with specific clues of asymmetrical multicomponent patterns as well as the parallel ridge pattern.

Raimonds Karls from Latvia talked about the challenge of mucosal pigmented lesions. He discussed the most common labial melanotic macules with their ring-like pattern and fish scale pattern. He discussed 91% of benign melanotic macules occurring on the lower lip and then discussed other challenging lesions including rare mucosal naevi, amalgam tattoos and clues to detect mucosal melanoma with asymmetry of structures and the presence of streaks.

The session concluded with **Cristian Navarrete-Dechent** from Chile talking about the challenge of lesions on the lower legs often confounded with the coexistence of venous stasis, pigmentary changes and chronic sun damage.

He highlighted that BCCs on the legs, below the knees, often have atypical features. He described that they commonly have glomerular vessels or polymorphic vessels rather than classical arborizing vessels. They can often mimic Bowen's disease. He then went on to discuss the challenge of naevi on the legs particularly after shaving and laser hair removal. He showed cases of lesion bleaching and irregular pigment blotches. He then showed how traumatic tattoos can dermoscopically mimic BCCs on the legs with blue ovoid nests.

Up-to-date treatments of hair, scalp and nail disorders

Boni Elewski from Alabama started with tips for treating onychomycosis and suggested not treating

until the fungus has been confirmed especially given rising resistance to antifungals. She discussed her use of prolonged courses of oral terbinafine, oral itraconazole (usually pulsed) and fluconazole. Her preference is to extend the course until cure is achieved with up to 6 months for terbinafine in toenail disease and 6 pulses of itraconazole (200mg bd for 1 week with 4 week break). She also described the use of fluconazole 200mg one to twice a week ("fungal Fridays") again until clearance achieved. She also gave a useful tip for stopping statins 2 days before and starting 2 days after pulses of itraconazole to try and prevent rhabdomyolysis.

Matilde Iorizzo from Switzerland talked about new treatments for nail psoriasis. She discussed intralesional methotrexate injections (25mg/ml) into the nail matrix on a 6 weekly basis for 6 months with a slightly better outcomes compared to intralesional steroids in a small study. She discussed new topicals on the horizon including cyclosporine compounded as hydrogel and tofacitinib. She also discussed the potential benefits of ducravacitinib (TYK2i) in nail psoriasis. In nail lichen planus she discussed the challenges in treatment and good results with tofacitinib but with the caveat that ongoing treatment is required.

Shari Lipner from New York gave us tips for treating brittle nails. Most cases are idiopathic but can be secondary to dermatologic conditions, systemic diseases and occupation. It often presents with onychoschizia and onychorrhexis. She discussed treatment options and in particular lifestyle measure including avoiding water and irritants, avoid nail cosmetics and the importance of nail moisturisation. She discussed that vitamins and supplements have no vigorous trials to support their use. Biotin deficiency is rare and is obtained in a normal diet and the evidence for oral biotin supplementation is weak. She also brought to our attention that biotin can interfere with lab test including thyroid function and cardiac enzymes and should be stopped before blood test. In terms of treatments she discussed the importance of lifestyle measure but improvement can be achieved with lacquers but these can be expensive.

Nilton Di Chiachio from Brazil discussed retronychia with proximal ingrowing of the nail. The underlying problem is that the nail does not grow forward. He discussed treatment options with anti-inflammatory and potent topical steroids in mild cases, intralesional steroid in moderate cases and nail avulsion in severe cases.

Brian Morrison from Miami talked about HPV-associated nail disease with a novel case report of local hyperthermia treating warts with a halogen tungsten lamp with good results in a child. He discussed reported success with the combination of fluorouracil and salicylic acid with 2-6 months of treatment. He also discussed the potential of intralesional cidovir and the MMR vaccine. Finally he showed a promising paper with the use of the nonavalent HPV vaccination clearing warts in some cases.

Adam Rubin from Philadelphia gave an update on his approach to managing melanonychia and the potential role of nail clippings to help in the diagnosis of nail unit melanoma as well as diagnosing other causes including blood and infection. He also highlighted the potential benefits of also being able to locate the origin in the nail matrix.

Antonella Tosti from Miami talked about when and how to prescribe oral minoxidil. She showed evidence of its use in numerous hair loss disorders. In AGA she recommended a dose of 0.25-2.5mg in women and 0.25 to 5mg in men. She discussed that side effects are dose dependent including hypertrichosis. She suggested avoiding in cardiovascular disorders, women with hirsutism and men with hypertrichosis. She discussed the possibility of ankle oedema and the extremely rare and unpredictable risk of pericardial effusion with just 3 cases in the literature. She discussed that the combination with low dose spironolactone (25mg) is to help with the potential of ankle oedema. She

suggested continuing topical minoxidil as well and warned that effects can take 6 months. She suggested stopping treatment one month before pregnancy.

Sergio Vañó-Galván from Spain gave us an update on anti-androgens including the potential use of oral dutasteride at a dose of 0.5mg 2-3 x week with an improvement in its side effect profile. He also discussed the use of topical finasteride 0.25% being almost as effective as oral finasteride. He also discussed mesotherapy with dutasteride in some selected cases being beneficial. He went on to discuss more novel anti-androgen including mesotherapy with bicalutamide, oral bicalutamide 10-50mg daily as well as the potential use of topical clascoterone.

Maryanne Senna from Massachusetts updated us on her use of JAK inhibitors for Alopecia areata and discussed a tool to use to evaluate the severity. She discussed her experience and dosing with tofacitinib and baricitinib.

Jerry Shapiro from New York updated us on 5-alpha reductase inhibitors. He discussed the use of topical finasteride 0.25% via a spray and its benefits of no systemic sexual side effects. He also discussed the potential use of dutasteride in mesotherapy.

Valerie Callender from Maryland then gave useful tips on managing dry itchy scalps in women of colour. She discussed different grooming practices as well as the importance of the frequency of shampooing (weekly or alternate weeks) and daily hair moisturisers. She also gave a useful tip that scalp itching and hair breakage can be seen in early or occult CCCA.

Amy McMichael from North Carolina gave us tips for managing Central Centrifugal cicatricial alopecia (CCCA). She highlighted that a ¼ have genetic underpinning and this can be important to let patients know rather than assuming relation to hair practices. She suggested using dermoscopy to check and treat any inflammation and to biopsy if not sure. She also discussed that seborrhoeic dermatitis may be related and there may be potential with 10% topical metformin but there is currently not enough data.

Dr Rodrigo Pirmez from Brazil discussed his technique in using mesotherapy. He highlighted the limited evidence but this is growing. He discussed the use of minoxidil, dutasteride and finasteride. He also discussed a novel technique of MMP with microinfusions into the skin using a tattoo machine.

Daniel Asz Sigall from Mexico discussed treatment of hair loss in transgender individuals. He discussed treatment of trans men with topical or oral minoxidil first line. He discussed that the effects of oestrogen on hair is controversial in trans women but again first line would be topical or oral minoxidil and then multiple anti-androgens.

Bruna Duque Estrada from Brazil gave a talk on a new method of injecting eyebrows using a cannula and ultrasound guidance to deliver steroids in a less painful technique with a diffuse pattern of hair regrowth.

Yolanda Lenzy from Massachusetts discussed ethnic hair care practices and numerous useful tips on hair cleansing weekly or biweekly and the importance of touching patient's hair when examining scalps. She also warned against the term protective styling and the importance of giving advice (such as loose cornrows or flat twists) rather than just telling patients what they can't do.

Marina Hordinsky from Minnesota gave an update on PRP and showed 2 FDA cleared devices but further studies are needed as well as further studies with hybrid products with hyaluronic acid to find optimal conditions.

Ronda Farah from Minnesota warned us about novel Exosomes product From mesenchymal cells and platelets. She warned that these are expensive, they are not FDA approved and there are concerns about potential infection and malignancy. Good studies are lacking.

The session concluded with **Martin Zaiac** from Miami giving an overview of painful nails with numerous nail tumours (onychomatrixomas, digital fibromas, pyogenic granulomas, exostoses and digital mucous cysts), nail deformities, inflammatory and infectious diseases (paronychia) and external agents.

Updates in hair disorders

The session was started by **Jerry Shapiro** from New York who discussed updates in Alopecia Areata. He discussed that oral minoxidil is now standardly used in combination with JAK inhibitors (JAKi) for severe disease. He showed data from Ritlecitinib (JAK3/TEC inhibitor) that seems extremely efficacious with mild adverse effects. He gave advice on the use of Baracitinib at 4mg daily giving excellent reduction in SALT scores (less than 20 i.e 80% scalp coverage). He looked at data showing little difference in performance between the JAKi but advised that SALT scores increase on stopping but you can down titrate in some. In terms of good candidates for JAKi he used the VICTIM mnemonic so to use in caution with patients with a history of Viral (hepatitis), Infections (TB), Coronary artery disease, Thromboembolic history, Immunisations and Malignancy. He recommends checking a full blood count, liver function tests, Quantiferon, hepatitis screen and pregnancy test prior to starting and then annually. He also recommended a lipid test at 12 weeks.

Natasha Mesinkovska from California discussed how she manages hair loss in women. She gave a number of top tips including asking about allergies in alopecia areata as a possible aggravating factor. She suggested that we ask what products patients are using again to look for potential allergies. She also suggested asking about previous scalp surgeries as well as the use of Botulinum toxin as Botulinum-induced frontal alopecia (BIFA) has been reported.

Sergio Vano-Galvan from Spain gave an update on hair surgery. He discussed the importance of selecting the correct patient and the fact in some cases medical management can negate the need for transplantation. He also highlighted the importance of ongoing medical management after transplantation. He then showed how his team performs transplant with micrografts. He also showed that excisional surgery is an option in some cicatricial alopecias.

Lidia Rudnicka from Poland gave an un update on dermoscopy (trichoscopy) for hair loss. She advised the use of trichoscopy in every patient with hair loss and reminded us that every patient could have two diseases of the scalp. She carefully went through dermoscopic signs in the hair shaft and the follicular openings to help with common hair loss conditions. She reminded us that the exclamation mark hair in alopecia areata is suggestive of activity and is a poor prognostic sign.

Elise Olsen from North Carolina gave an update on 5-alpha reductase inhibitors in women with hair loss. She went through the evidence and side effect profiles of finasteride and dutasteride. She suggested the use of 1-2.5mg finasteride and showed that there is no reason not to use 5mg. Dutasteride 0.5mg is more effective but with a longer half-life. Both finasteride and dutasteride are effective for women with AGA. She advises against the use of dutasteride in women of child bearing age and to ensure using contraception if using finasteride. She showed some evidence for the use of topical finasteride as well as in combination with minoxidil.

Kristen Lo Sicco from New York talked about anti-androgens for Androgenetic Alopecia for both injectables and topicals. She showed benefits of topical finasteride 0.25% daily in combination with 5% topical minoxidil. She also showed some interesting potential benefits with 2% Ketoconazole shampoo (3-7 x week) use for AGA. She also showed encouraging data with Clascoterone 7.5% solution twice daily. She also confirmed potential benefits of mesotherapy (transdermal microinjections) of dutasteride every 3 months with minimal side effects.

Pearl Grimes from California gave an update on Central Centrifugal Cicatricial Alopecia (CCCA). She showed that this is a truly devastating disease to those affected in Quality of Life studies. She showed some studies showing a relationship with CCCA and seborrheic dermatitis. Pathogenesis involves genetics, possible grooming practices (chemicals, heat, dermatitis and trauma) and low vitamin D.

Leonard Sperling from Maryland talked about what's new in pathology of hair disease in the last 2 years. He showed a paper that showed sebaceous gland atrophy as a dependable and distinctive sign in seborrheic dermatitis and possible psoriasis. He discussed the importance of biopsying the correct site (not bald spots in cicatricial alopecia) and the use of a dermatoscope to aid the correct site. He also advised the importance of good clinical information for the pathologist.

Rodney Sinclair from Australia talked about the use of low dose oral minoxidil. He explained that minoxidil is poorly soluble and the maximum topical concentration is 5% (It has stability issues above this). Percutaneous absorption is also low 1.5-4% and therefore oral minoxidil has benefits.

Rodrigo Pirmez from Brazil discussed his approach to managing Frontal Fibrosing Alopecia. He discussed the complexity in managing the condition and each patient is unique depending on the features present. As it is a scarring condition he treats early and aggressively. His first line systemic agent is hydroxychloroquine with doxycycline being an alternative. He tends to add in dutasteride or finasteride as well. He uses tacrolimus topically due to concerns of atrophy with potent topical steroids and uses 2.5mg/ml of triamcinolone for ongoing inflammation on a 4-6 weekly basis. He uses oral minoxidil 1.25mg in all cases to help with hair density. His second and third line treatments tend to be methotrexate and ciclosporin. He treats eyebrow alopecia with triamcinolone and sometimes bimatoprost. For facial papules he uses isotretinoin with a loading dose of 40mg daily for 2 weeks and then maintaining on 10-20mg 2-3x week before trying to taper in 3-6 months. He advises all his patients to avoid sunscreen on the hairline.

Leopoldo Santos from Brazil talked about procedures beyond PRP and transplantation and specifically about mesotherapy and a tattoo machine (MMP) to deliver drugs including dutasteride and minoxidil. He showed us how to do a scalp ring block to make the procedure more comfortable.

Finally, **Azael Freties-Martinez** from Spain discussed alopecia in cancer patients and survivors. He discussed chemotherapy-induced alopecia (CIA) and the potential of scalp cooling systems helping in 50%. There is 15-30% chance of persistent chemotherapy induced alopecia (pCIA). He used to manage this with 5% topical minoxidil but now uses oral minoxidil 0.5-5mg daily. He does not use finasteride but an option is spironolactone 200mg daily. He also discussed endocrine therapy induce alopecia (from tamoxifen or aromatase inhibitors) with management being similar to pCIA.

Pearls: diagnostic and therapeutic

The session was started by **Morgan Wilson** from Illinois who gave us some clinicopathological

pearls. He showed us that fungus and hypertrophic lichen planus can mimic Squamous Cell Carcinomas especially when numerous SCCs are diagnosed on the lower legs. He then discussed the use of the PRAME (PRefentially expressed Antigen in Melanoma) immunohistochemistry stain in helping to diagnose melanoma. He showed that when diffusely positive (with 76-100% cells stain) this is more common in melanoma than naevus.

Mark Lebwohl from New York gave us some further pearls. He discussed the use of an IL-36 blocker (Spesolimab) in sick patients with acute generalised pustular psoriasis with one infusion causing clearance within 24 hours. He also showed a dramatic case of extensive ulcerative pyoderma gangrenosum not responding to a TNF blocker, high dose prednisolone and ciclosporin but with a dramatic response to Spesolimab infusions. He then showed a case of extensive Darier's disease previously not responding to topicals and oral acitretin but responding to bexarotene 150-300mg daily (pre-treat with statin, monitor thyroid function and start low dose levothyroxine to reduce side effects). He finished his talk with showing case reports of the potential of JAK inhibitors for numerous resistant inflammatory dermatoses.

Rebecca Larson from Illinois gave some surgical procedural pearls. She showed us the use of micropore tape on a simple tape dispenser to assist nursing staff applying dressings. She showed some useful dressing for the scalp (pony-tail dressing), using a shower cap to protect ear dressings and a novel nasal pack made from the tip of a surgical glove, a cotton ball and Vaseline to keep in the nose for 24-hours post-surgery. In terms of procedural tips she gave an excellent tip of using steri-strips placed horizontally along the wound in extremely fragile skin before suturing.

Aimilios Lallas from Greece gave his dermoscopy pearls and recommended that dermoscopy should be used in the evaluation of all skin lesions. He discussed the importance of symmetry and asymmetry in trying to detect malignancy. He showed the use of pigmented structures (blue globules) in diagnosing BCCs. He showed how dermoscopy can help determine subtypes of BCC for example blue globules can help in detecting nodular components in mixed superficial and nodular basal cell carcinomas. He showed the use of detecting white peri-follicular circles as a diagnostic clue for squamous cell carcinoma. He highlighted useful tips for detecting naevus-associated melanoma with polygonal (grey polygons) lines and an inverse network. He then gave some tips for using dermoscopy in inflammatory skin conditions including white crossing lines in lichen planus and yellow scale in eczema and white scale and dotted parallel lines of blood vessels in psoriasis.

Stephen Stone from Illinois finished the session and gave some more practical pearls. He started with localised neuropathic pruritus (notalgia paraesthetica, brachioradial pruritus) and suggested the use of naltrexone 50mg daily with side effects including nausea and fatigue. He also recommended a product called Dermeleve with strontium bought over the counter as well as reports of benefits of butorphanol nasal spray. He discussed the use of N-acetylcysteine for trichotillomania, nail biting and skin picking at a dose of 2000mg per day for a 6-month course. In Hailey-Hailey disease he advised acitretin between 10-25mg day and another option of naltrexone for associated itch. He finished with a few mini pearls including: red scrotum syndrome he suggested doxycycline 100mg twice daily sometimes being helpful. He suggested biopsying unilateral inguinal fold rashes. Silver nitrate cautery in aphthous stomatitis to speed up healing. In generalised Granuloma annulare he suggested methotrexate 15mg per week. He discussed the use of apremilast as a mouth wash for treating lichen planus (2 x 30mg tablets in water bottle 2 x week) leading to 80% improvement. He discussed getting patients to remove their apple-type watches prior to skin surgery due to their potential damage when using a hyfrecator. He gave advice for smelly feet with the use of clindamycin gel, BPO wash in shower and topical metronidazole (also useful for smelly venous ulcers as well). He also discussed the use of ultrasound gel to a viral wart before cryotherapy as it can increase the freezing time, improve the rate of treatment efficacy, and reduce the adverse events associated with cryotherapy.

Challenging cases of dermoscopy

My final session of the AAD was hosted by **Joel Claveau** from Canada and **Aimilios Lallas** from Greece with numerous interactive dermoscopy cases.

Joel Claveau showed a difficult seborrheic keratosis and highlighted the importance of both modalities of dermoscopy when using hybrid devices as the non-polarised mode will show the milia-like cysts to aid the diagnosis. He showed the importance of symmetry in benign melanocytic lesions and examples of melanoma specific structures including atypical streaks and a blue-white veil. He showed a challenging case of Bowenoid papulosis in the groin with multiple grey dots aligned in a linear fashion. His next case highlighted the importance of age with an atypical rim of globules around a naevus in a melanoma in-situ. He showed a negative pigment network as a marker of melanoma as well as a nodular spitz naevus with shiny white streaks and dotted vessels in a child.

Aimilios Lallas then showed a few facial cases and reminded us of his inverse approach in helping detect early lentigo maligna. He showed pigmented actinic keratoses with scale, rosettes and erythema as well as white and wide follicular openings (WWF). He showed the sharp demarcation with an abrupt stop at edge in solar lentigo and milia-like cysts and comedo-like openings in classical seborrheic keratoses. He showed us that a pigment network on the face is most likely to be a solar lentigo. He described that in the inverse approach if none of the six non-melanoma features are present as the predominant feature then lentigo maligna should be suspected (the 6 non-melanoma features being scale, white and wide follicles, erythema and reticulate vessels, Fingerprinting, sharp demarcation and classic SK criteria). He then discussed ways of picking up early SCC with the presence of white structureless areas, dotted vessels and ulceration. His last case was that of erosive pustular dermatosis with dermoscopy showing multiple vessels and some pustules. He discussed the potential of systemic retinoids in recalcitrant cases.

Joel Claveau then completed his cases with a challenging case of an atypical fibroxanthoma with red and white structureless areas. He then showed a case of stasis dermatitis on the leg with dotted vessels and yellow crust mimicking squamous cell carcinoma in-situ. He highlighted the challenge of a recurrent naevus on the back mimicking melanoma (pseudomelanoma) with a rim of pale scar tissue as well as a difficult case of amelanotic melanoma on the scalp mimicking basal cell carcinoma. He had two further extremely challenging cases that reminded us of the importance of examining all skin lesion with dermoscopy with a verrucous seborrheic keratosis-like melanoma as well as metastatic melanoma mimicking squamous cell carcinoma.

Reports written by

Dr. H el ene Veillette

Dermatologist, Quebec

JAAD Game Changers

Systemic treatment of psoriasis reduces mortality. This was established based on robust data from the PSOLAR registry.

In Denmark, it has been shown that in patients with systemic lupus, major cardiac events are reduced by taking hydroxychloroquine.

Oral minoxidil is a new option for AGA and has an excellent safety profile (1.7% of patients have side effects). The side effects are as follows:

1. Tachycardia (first 24 hours)
 2. Light-headedness (one to seven days)
 3. Headache (15 to 20 days)
 4. Hypertrichosis (one to three months)
 5. Oedema (one to three months)
-

HS surgery from start to finish

Ensure that the lesion to be operated on is not too inflammatory. If necessary, treat with an intra-lesional corticosteroid (suggested dose: 20 to 40 mg/ml) and postpone surgery for one to two weeks. Curettage of the bottom of the fistula is important, to thoroughly remove the biofilm.

The complications of deroofing are as follows:

1. Bleeding: ensure proper cauterisation, apply a compression bandage, and limit vigorous physical activity for 24 to 72 hours
2. Hypergranulation: treatment with a potent corticosteroid can be attempted. The alternative is to remove the hypergranulation surgically and make sure there is no residual fistula that could explain the phenomenon
3. Infection (uncommon)

It is safe to continue biotherapy in the post-operative period.

The following factors do not influence the time to recovery: body mass index, smoking, diabetes, number of surgical sites

Finding solutions to challenging cases

Infantile myofibroma: single lesion or multiple lesions: a chest X-ray, an echocardiogram and a whole-body MRI scan with and without contrast are recommended. Consider close follow-up every three to six months.

In a patient who has taken cyclosporine, if there are multiple papules, consider the diagnosis of cyclosporine-induced sebaceous hyperplasia (can appear several years after discontinuation). The usual treatments for sebaceous hyperplasia can be attempted, including isotretinoin.

In a patient with moderate to severe psoriasis and melanoma, consider IL-17 and IL-23 inhibitors, or apremilast. Avoid JAK inhibitors and anti-TNF agents.

Side effects may include: illustrative cases of dermatologic adverse events

Fixed pigmented erythema: Consider the following medications: Bactrim, doxycycline, tetracycline, NSAIDs, acetaminophen, vaccines and some more recent medications such as biotherapies.

Vemurafenib can induce panniculitis. This usually occurs around two weeks after the start of treatment. Treatment is optional as the lesions may resolve spontaneously. NSAIDs and systemic corticosteroids may be attempted depending on the clinical picture.

Voriconazole can induce phototoxic reactions.

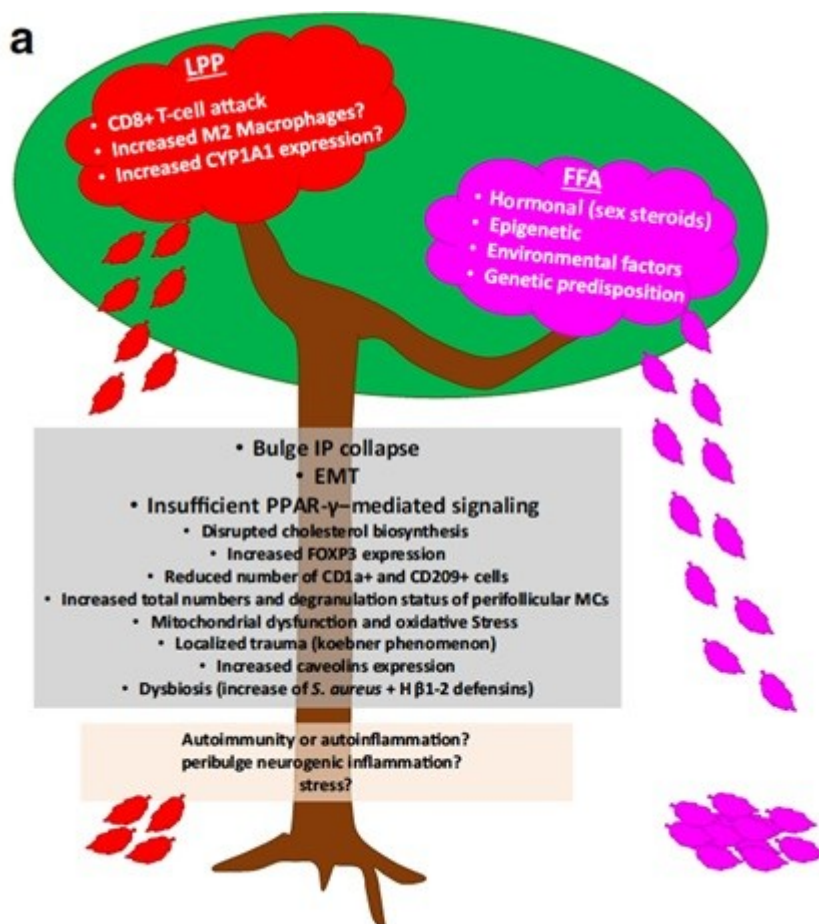
Dupilumab, probably through suppression of the Th2 pathway and the relative reactive increase in Th17 that may occur, can induce arthritis, enthesitis and psoriasis. The median time to onset of these symptoms is 16 weeks. The symptoms may resolve on discontinuation of the medication, but sometimes this takes several months.

Unravelling frontal fibrosing alopecia: current landscape and challenges

1. Physiopathology

According to the speaker (Dr Maria K. Hordinsky), this article summarises the topic well: Senna, Maryanne Makredes et al. “Frontiers in Lichen Planopilaris and Frontal Fibrosing Alopecia Research: Pathobiology Progress and Translational Horizons”. JID Innovations: Skin Science from Molecules to Population Health vol. 2,3 100113. 1 Mar. 2022, doi:10.1016/j.xjidi.2022.100113

Here is a diagram taken from this article she presented that shows the physiopathological differences between FFA and LPP:



In addition, here is a table that summarises the clinical and histopathological differences between the two diseases (taken from the same article):

Table 1. Clinical and Immunohistopathological Characteristics of FFA and LPP

Diagnosis	Distinct Histopathological Characteristics ¹	Shared Histopathological Characteristics	Distinct Clinical Characteristics	Shared Clinical Characteristics
LPP	<p>More severe inflammatory infiltrate and less apoptosis (Problet et al., 2006; Gálvez-Carseco et al., 2018)</p> <p>Concentric lamellar fibroplasia (Gálvez-Carseco et al., 2018)</p> <p>More basilar layer and interfollicular epidermal damage (Problet et al., 2006)</p> <p>Increased melanocyte counts in the upper hair follicle (Katoulis et al., 2020)</p> <p>DIF shows less IgM immunofluorescence and IgG, IgA, and IgM in papillary dermis (Cerqueira et al., 2016)</p> <p>Increased CD68⁺ macrophage polarization and upregulated CD163 and IL-4 (Harries et al., 2020)</p>	<p>Lichenoid perifollicular lymphocytic infiltration (most evident in the superior aspects of the hair follicle) (Kurzeja et al., 2021; Stefanato, 2010)</p> <p>Infundibular hyperkeratosis and hypergranulosis.</p> <p>Hair epithelium shows vacuolar degeneration, necrotic keratinocytes, and perifollicular loss of elastin fibers with fibrosis (Ma et al., 2017)</p> <p>Superficial pigment incontinence (Wilk et al., 2013; Bolduc et al., 2016)</p> <p>Follicular plugging, epidermal/dermal clefts, and sebaceous gland destruction (Kang et al., 2008)</p> <p>The chronic stage shows dilated blood vessels and band-like vertical scarring beneath the papillary dermis (Kang et al., 2008)</p>	<p>Asymmetric multifocal involvement of scarring alopecia (Bolduc et al., 2016)</p> <p>Perifollicular erythema and keratotic follicular papules (Bolduc et al., 2016)</p> <p>Most commonly vertex and parietal scalp, but all regions can be involved (Stefanato, 2010)</p> <p>Association with oral, ungual, or cutaneous lichen planus (Bolduc et al., 2016)</p> <p>Dermoscopy shows elongated concentric blood vessels, violaceous-blue interfollicular areas, and big irregular white dots (Bolduc et al., 2016)</p>	<p>Dermoscopy shows loss of follicular ostia, peripilar white scales, and peripilar erythema (Bolduc et al., 2016)</p> <p>Symptoms of pruritus, pain, and burning (Vaňó-Galván et al., 2014)</p>
FFA	<p>Extension of the inflammatory infiltrate below the isthmus (Wong and Goldberg, 2017)</p> <p>Islands of sparing of interfollicular epidermis (Harries et al., 2013)</p> <p>Less prominent inflammatory infiltrate, with more numerous necrotic keratinocytes and foreign body reaction (Problet et al., 2006)</p> <p>More frequent terminal catagen-telogen hairs (Gálvez-Carseco et al., 2018)</p> <p>DIF shows cytooid bodies of IgM in the papillary dermis and epidermal and follicular basement membrane zones (Cerqueira et al., 2016)</p> <p>Increased Langerhans cells in the infundibuloisthmic region compared with that in LPP (Ma et al., 2017)</p>	<p>The late stage shows extensive perifollicular lamellar fibrosis surrounding the infundibulum (Kang et al., 2008)</p> <p>Similar expression profiles of CD1a, CD3, CD4, CD8, CD68, and IDO in immunohistochemical studies (Cerqueira et al., 2016)</p> <p>Increased CD8⁺, CXCR3⁺, FOXP3⁺ T cells, and CD68⁺ macrophages (Harries et al., 2020)</p> <p>Increased total and degranulated mast cells and CD123⁺ dendritic cells (Harries et al., 2020)</p> <p>Decreased numbers of CD1a⁺ and CD209⁺ dendritic cells in the infundibulum connective tissue sheath (Harries et al., 2020)</p>	<p>Symmetric, progressive frontotemporal hairline recession in a band-like pattern above the patient's normally pigmented and wrinkled forehead.</p> <p>Less frequent recession of preauricular and postauricular areas and occipital scalp.</p> <p>Dermoscopy shows peripilar white scales and erythema, regularly distributed red or gray dots in eyebrows, and peripilar erythema (Bolduc et al., 2016)</p> <p>Skin-colored facial papules.</p> <p>Marked or complete loss of eyebrows, typically beginning laterally (Bolduc et al., 2016)</p> <p>General thinning of the beard and peripheral body hair.</p> <p>Absence of vellus hair in the hairline.</p>	

Abbreviations: DIF, direct immunofluorescence; FFA, frontal fibrosing alopecia; LPP, lichen planopilaris.

¹Although several studies have found histopathological differences between LPP and FFA, all concluded that the findings are too subtle to distinguish the entities without clinical correlation.

60% of FFA patients and 80% of LPP patients have inflammation in normal-appearing areas of the scalp.

2. Diagnosing FFA

Three clinical patterns: linear (48.8%), diffuse (45%, worst prognosis), double lines (6.2%, best prognosis)

Alopecia of the eyebrows (non-scarring): 73 to 95%

Loss of facial hair and occipital hair is possible

Loss of other body hair (non-scarring alopecia): pubic area and underarms, up to 50% of patients

Small facial papules with changes in skin texture: mostly on the temples, up to 22% of patients (low-dose isotretinoin (e.g. 5 to 10 mg/day) may be effective)

Rosacea-like eruption (erythema of the cheeks in particular)

Depression of facial veins, especially on the forehead

Hyperpigmentation (lichen planus pigmentosus): especially in dark-skinned people; face, neck, skin folds

Hypopigmentation: upper forehead, eyebrows, sometimes associated with vitiligo

3. Treating FFA

Here is the summary presented by Dr Sergio Vaňó-Galván

FRONTAL FIBROSING ALOPECIA: SUMMARY OF THERAPIES 2023

+/- JAKI ?


A) TREATMENT FOR DECREASING INFLAMMATION	SLIGHT INFLAMMATION	Topical tacrolimus or pimecrolimus (preferred) or topical steroids 1-2 days per week
	MODERATE INFLAMMATION	Intralesional triamcinolone 4 mg/mL every 3 months. Consider antimalarial drugs and/or platelet rich plasma. Excimer laser .
	INTENSE INFLAMMATION	Intralesional +/- systemic steroids. Consider antimalarial drugs / doxycycline / pioglitazone.

+

B) TREATMENT FOR REGULATING THE HORMONAL IMBALANCE	- Dutasteride 0.5 mg 5-7 / week (preferred) vs 3 / week
	- Finasteride 2.5 – 5 mg daily

+

C) TREATMENT FOR IMPROVING THE AESTHETICS	-If facial papules: oral isotretinoin 5-10 mg daily
	-Eyebrows /scalp micropigmentation
	-Minoxidil 2%-5% vs oral minoxidil
	-Hair integration systems / wigs / FAS systems
D) SURGICAL TREATMENT (only selected cases!!)	-If skin atrophy: consider platelet rich plasma
	-FFA should be clinically stabilized for at least 1 year -Hair transplantation should be performed in small areas -Discuss with the patient the durability of the grafts (40% after 5 years)!!



Reports written by

Prof. Jihee Kim

Dermatologist, South Korea

Managing unique conditions in Asian Skin

Since the Asian population is increasing and almost 60% of the world is Asian, the demand for experienced dermatologic care for Asian skin will increase. This session was directed to suggest dermatologists learn to diagnose and treat common medical and cosmetic issues.

Dr. Hye Jin Chung presented an updated review on the approach to scars in Asian patients. When intralesional steroid injections fail to treat keloids or hypertrophic scars, Dr. Chung suggests fluorouracil/steroid injections, fractional ablative laser assisted drug delivery, or pulsed dye laser. She also discussed a detailed technique of keloid removal with a fillet flap in Asian patients.

Dr. Woraphong Manuskiatti presented clinical features and treatment options for common benign facial pigmented lesions in Asians. Solar lentigines, melasma, seborrheic keratosis, ABNOM, and PIH are common in Asians because melanocytes in Asian skin respond differently to visible light than in white skin. Visible light induces pigmentation that is darker and more persistent. He suggests treatment with a low fluence picosecond laser for melasma and use of concomitant oral tranexamic acid.

Dr. Jihee Kim presented special cosmetic considerations in neurotoxin, fillers, other 'skin boosters', and laser therapy in Asian patients. She stated that superficial dermal injections of neuromodulator (with or without intradermal injections of hyaluronic acid) and injections of poly-D,L-lactic acid or polynucleotide are common and successful anti-aging techniques.

Dr. Davinder Parsad discussed current developments in the treatment of pigmentary disorders, such as autologous non-cultured epidermal cell suspension for vitiligo and medicinal and laser treatment for acquired dermal macular hyperpigmentation.

Greatest cases from the Dermatopathology Slide Club

In this interactive session, selection of educational and instructive dermatopathology cases were discussed along with clinicopathologic correlation and recent updates in dermatopathology.

Drs. Kara M. Braudis, Nicholas Logemann, Palak Kishorkumar Parekh, Melissa Piliang, Michi Shinohara, Campbell Stewart, and Wendi E Wohltmann from 'Dermatopathology slide club' shared interesting and educative cases, including various inflammatory (ischemic alopecia with therapeutic embolization, phytophotodermatitis etc.) and infectious disease (rat bite fever, blastomycosis, etc. as well as cutaneous malignancies (cutaneous endometriosis, cutaneous acral angiomatous hamatoma, spiradenoma with sebaceous and squamous differentiation, metastatic breast cancer etc.)

What's new in Dermatopathology?

This session provided an up to date coverage of cutaneous neoplasia, inflammatory skin disease, dermoscopy, molecular methods, translational research, and cutaneous infections.

Dr. Iwei Yeh presented "Updates in melanocytic neoplasia" in regards to pathology reporting and 8th AJCC staging. In 8th AJCC staging of primary cutaneous melanoma, T-category is determined by Breslow thickness and ulceration with cutoff point of 0.8 mm for tumor thickness. When measuring Breslow thickness, either excision or biopsy specimen, whichever the greatest is indicated and measurement around adnexal structures should be avoided. N-category is determined by number and extent of nodal disease and satellites, where most lymph node metastasis are detected by examination of the sentinel lymph node. M-category includes site of metastasis as well as LDH level. Recently PRAME immunohistochemistry (IHC) is suggested as a helpful adjunctive IHC modality yet its sensitivity and specificity may appear in different subtypes of melanoma. There are PRAME-negative melanomas and PRAME-positive melanocytic nevi; hence, connection with histopathologic and clinical characteristics is required.

Dr. Kiran Motaparathi presented "Inpatient dermatopathology" encompassing commonly encountered diagnostic mimickers within inpatient dermatology consultations. Toxic epidermal necrolysis (TEN) is a life-threatening condition commonly elicited by drugs. In this talk, simulators of TEN including, Toxic erythema of chemotherapy, drug-induced linear IgA disease and Acute generalized exanthematous pustulosis were described with case presentations. Additionally, cases of calciphylaxis, nutritional deficiency, acute graft-versus-host-disease and neutrophilic dermatosis due to cryptococcus infection were presented.

Rheumatology for the dermatologist: evaluating the rheumatology patient in the dermatology clinic

This session reviewed rheumatology disease with skin manifestations such as systemic lupus erythematosus and dermatomyositis to provide insights for dermatologists to approach systemic rheumatologic disease. Due to overlapping agenda within session S017, I focused on the session on dermatomyositis.

Dr. Scott Elman presented “Dermatomyositis: Systemic Considerations for the Dermatologist”. Dermatomyositis is an uncommon inflammatory disease marked by muscle weakness and a distinctive skin rash presenting with two distinctive phenotypes; juvenile dermatomyositis (JDM) and adult dermatomyositis (DM), which can be further classified as a clinically amyopathic dermatomyositis (CADM) or hypomyopathic dermatomyositis. When evaluating a patient suspected for DM, systemic evaluation including skin, muscle, lung involvement as well as screening for potential malignancy. Treatment recommendations for patients with DM are based on disease severity, the presence of systemic symptoms, and myositis-specific antibody (MSA) profiles. The difficulty in interpreting MSA profiles exists due to serologic gap within patients with DM who test negative and clinically available tests vary in sensitivity and specificity. Thus, real-world MSA positivity with confirmed DM patients are reported between 20~50%. Recent studies have provide data on certain MSA is linked with more prominent DM phenotype.

- Anti-TIF1-gamma: Widespread disease, psoriasiform lesions, “Red/white” patches , and hyperkeratotic papules on hand
- SAE2: Diffuse erythema with ‘angel wings’ sign
- Anti-Jo-1: Mechanic’s Hands

In the presence of DM-specific skin lesion, proximal muscle weakness and/or elevated muscle enzymes, less invasive procedures compared to muscle biopsy, such as skin biopsy, EMG or MRI can be done. Malignancy work up in all DM patients is controversial yet, recent studies have specified predictors of malignancy associated DM. Therefore, thorough medical history, physical examination, and laboratory testing is necessary along with age=appropriate cancer screening.

Treatment approach to DM depends on the presence and severity of underlying muscle disease, presence of malignancy, and presence of interstitial lung disease. As a general measure, strict sun protection with topical corticosteroids and calcineurin inhibitors are used. Systemic immunosuppressants such as methotrexate, mycophenolate mofetil and IVIG have shown efficacy to date. Additionally, the use of JAK inhibitor (Tofacitinib) is reported in refractory DM patients.

Atopic dermatitis

This session provided an up-to-date overview of atopic dermatitis (AD), new findings, and new therapeutics. It also emphasizes the high burden and comorbidities of AD, and identifies barrier and immunological alterations in AD that serve as the basis for new treatments.

Dr Drucker and Dr Beck presented an overview of the AD epidemiology and comorbidities and the role of the epidermal barrier, respectively. Dr Guttman-Yassky presented the immune system shifts in AD based on the comprehensive review on the translational studies.

AD is well known as a Th2-polarized disease, while In the chronic lesion of AD, Th1 cells are considered to induce chronic eczema with thick epidermis. Within past decade there have been a paradigm shift in pathogenesis of AD; Different phenotypes of AD, defined according to the patient age at onset, race, and ethnic background; disease duration; and other disease characteristics, have been recently described, underlying the need for a personalized treatment approach. Recent advancements in understanding AD pathogenesis resulted in a real translational revolution and led to the exponential expansion of the therapeutic pipeline. The study of biomarkers in clinical studies of emerging treatments is helping clarify the role of each cytokine and immune pathway in AD and will enable the identification of the distinct immunological fingerprints of each AD subtype.

Translational approach in AD can be done by;

1. Defining AD-specific biomarkers in skin and blood can help to identify pathogenic pathways and develop precision medicine approaches
 2. Skin profiling is considered the gold standard, linking cytokine activation, barrier defects and disease severity
 3. Blood profiling may still be useful for patient stratification and therapeutic selection
 4. Development of minimally-invasive skin biomarkers is important in both adults and particularly in children, where obtaining skin biopsies may be impossible
 5. Tape-strips may provide useful means to investigate biomarkers in pediatric settings and in large clinical trials or longitudinal studies where biopsies are not practical
-

Acne and rosacea

This session provided an update on the treatment options for acne and rosacea including the uses of systemic medications.

Dr. Diane M Thiboutot presented novel insights in acne pathogenesis. Drivers of inflammation in the acne microenvironment includes *C. acnes*, antimicrobial Th17 cell clones and TREM- expressing macrophages. Firstly, among various phylotypes of *C. acnes*, acne subjects have greater proportions of *C. acnes* ribotypes 4 and 5. *C. acnes* phylotypes may have an increased propensity to induce acne due to induction of both Th1 and Th17 responses compared to healthy phylotypes. Meanwhile, the *C. acnes* strains associated with health induce Th17 clones that secrete molecules sufficient to kill *C. acnes* by differentially modulate the CD4+ T cell responses, leading to the generation of Th17 cells. Therefore, *C. acnes* induces antimicrobial TH17 clones that trap and kill bacteria by T cell extracellular traps (TETs). TREM2 macrophages present in proximity to hair follicle epithelial cells and acne lesions are enriched with foamy macrophages expressing TREM2. Additionally, squalene, which is overproduced in acne lesions, induces TREM2 macrophages with enhanced phagocytic capacity for lipids and *C. acnes*, but squalene scavenges oxygen radicals, thus blocking the macrophage antimicrobial response. An increased understanding of the inflammatory drivers in acne, including strain differences of *C. acnes* may provide opportunities for therapeutic intervention.

Dr. Del Rosso presented the use of oral antibiotics therapy in acne vulgaris and rosacea. Broad-spectrum antibiotics such as tetracycline, doxycycline and minocycline have been used for over 1000 years with favourable safety profiles for chronic use. Commonly stated perspectives on oral antibiotic therapy for acne includes the component of recognized guidelines for moderate to severe acne especially for inflammatory lesions. Combination with topical therapy (especially benzoyl peroxide) can augment efficacy and reduce adverse sequelae. Anticipate a 3-6 months course of therapy with a discussed exit plan to limit exposure.

Sarecycline is defined as a narrow-spectrum tetracycline approved by FDA on 2018. Antibiotic activity of sarecycline versus *C. acnes* is comparable with doxycycline and minocycline with low propensity for *C. acnes* resistance. Additionally, narrow spectrum of antibiotic activity of sarecycline may correlate with a decreased tendency to disrupt normal flora including the GI tract microbiome.

Dr. Julie Claire Harper presented novel therapeutic insights in rosacea. First, classic subtypes of rosacea are no longer emphasized since different lesions/signs of rosacea will require multiple modes of treatment, and a combination treatment approach is necessary for most patients. The importance of mast cell stabilizers has been raised based on studies on rosacea triggers where inflammation

through innate immunity and neurogenic dysregulations are suggested. Increased number of mast cells in the dermis of lesional rosacea skin vs uninvolved skin and mast cells are the key mediators of LL-37-induced rosacea inflammation. Among various mast cell stabilizers, hydroxychloroquine (HCQ) showed comparable efficacy with doxycycline and is generally deemed safe during pregnancy and may be an alternative treatment for women with rosacea. Additionally, 5% microencapsulated benzoyl peroxide cream gained FDA-approval for inflammatory lesions of rosacea. Oral sarecycline and low-dose minocycline which showed efficacy for acne have demonstrated in several clinical studies and can be an emerging treatment option for rosacea.

Reports written by

Dr. Joël Claveau

Dermatologist, Quebec

A tidal wave is coming: cutaneous immune-related adverse events from immune checkpoint inhibitors

Steven T. Chen, Harvard Medical School, Boston, Jennifer N. Choi, Northwestern University, Chicago, Bernice Kwong, Stanford University, Palo Alto, USA

The cutaneous side effects of cancer immunotherapy were presented during this symposium. The number of indications for these treatments is constantly increasing (melanoma, various cutaneous and mucosal carcinomas, lung cancer, kidney cancer, urogenital and gynaecological neoplasms, some forms of lymphoma and leukaemia, neurological cancers, etc.). The main drugs used include PD-1 inhibitors (pembrolizumab, nivolumab and cemiplimab), PD-L1 inhibitors (atezolizumab, durvalumab and avelumab), CTLA-4 inhibitors (ipilimumab), and LAG inhibitors (relatlimab). Cutaneous side effects occur in 40% of patients and considerably affect their quality of life. The rash usually starts within the first three months but can occur at a late stage, even after stoppage of treatment. Interestingly, the development of an immune cutaneous side effect is associated with improved patient survival. Some common side effects include isolated pruritus, a maculopapular rash, eczematous dermatitis, a lichenoid rash, psoriasis, and vitiligo. Most of the time, immunotherapy does not need to be stopped and the rash can be controlled by using the right amount of topical steroids. For rarer or more severe rashes, dermatological intervention is important and the use of systemic steroids or other systemic agents is recommended. The wide variety of conditions reported have included bullous pemphigoid, cutaneous sarcoidosis, Sweet syndrome, panniculitis, and a severe rash characteristic of Stevens-Johnson syndrome, also called toxic epidermal necrolysis. Management of these severe cases will require a multidisciplinary approach and often a transfer to a specialised care unit (intensive care, burn unit, etc.).

Merkel cell carcinoma: diagnosis, management, and controversies

Kelly L Harms, MD, PhD, FAAD, Michigan Medicine, Ann Arbor, USA

The management of patients with Merkel cell carcinoma (MCC) requires a multidisciplinary approach at all stages. MCC is a rare neuroendocrine carcinoma; it is estimated that there are around 2,800

cases/year in the United States compared with 5,400,000 cases of basal and squamous cell carcinomas. This tumour has a high risk of lymph node involvement and metastasis. The average age of patients is around 70 years. The main risk factors are being over 60, sun exposure, and immune suppression. Merkel cell polyomavirus was discovered and associated with this carcinoma in 2008. This carcinoma often has a non-specific presentation and the acronym AEIOU can help in the diagnosis (*A: asymptomatic, E: expanding rapidly, I: immune suppression, O: older than 50 years, U: UV exposure*). The tumour is usually reddish or purplish and grows rapidly for two to three months; it usually occurs in a photo-exposed area. For the histological diagnosis, it is a small-round-blue-cell tumour resembling small-cell lung cancer or lymphoma. The diagnosis is confirmed by immunohistochemistry with perinuclear staining with CK20 and other neuroendocrine markers as well as negative TTF-1 staining. The presence of polyomavirus is associated with a better prognosis and may be useful in the follow-up of patients.

In terms of management, if the clinical examination and radiological tests (usually a PET-CT scan) do not reveal enlarged lymph nodes, the sentinel node technique should be performed in all cases as the positivity rate is above 15-20%. In the rare cases where a resection margin of at least 1 cm is difficult to achieve (e.g. eyelid, nostril), Mohs surgery can be offered to the patient. Otherwise, a 1-2 cm margin should be offered and should be followed by additional radiotherapy at the local excision site for tumours > 1 cm. Usually, for clinical (palpable or radiological) lymph node involvement, the patient is offered complete lymph node dissection and sometimes even additional postoperative radiotherapy. For patients with sentinel node involvement, the approach will be more conservative, usually with radiotherapy to the affected nodal basin. Lastly, there is still no accepted adjuvant treatment for high-risk stage III patients, but immunotherapy (PD-L1 inhibitor/avelumab or PD-1 inhibitor/pembrolizumab) is increasingly standing out as a first alternative for inoperable stage III patients or stage IV patients, with a longer response time than with conventional chemotherapy (carboplatin or cisplatin + etoposide).

Don't miss any congress reports



ECOBIOLOGY AT THE SERVICE OF DERMATOLOGY

Learn more about NAOS, French ecobiology company
founder of BIODERMA, on www.naos.com